



Contents lists available at ScienceDirect

## Journal of Diabetes and Its Complications

journal homepage: [www.elsevier.com/locate/jdiacomp](http://www.elsevier.com/locate/jdiacomp)

# Reversal of diabetic retinopathy in two patients following the use of physiologic insulin Resensitization

Randal T. Pham<sup>a</sup>, Aarin Pham-Hoang<sup>a</sup>, Stanley T. Lewis<sup>b</sup>, Frank Greenway<sup>c</sup>, Amr Dessouki<sup>d</sup>, Richard M. Grimes<sup>e,\*</sup>

<sup>a</sup> California Northstate University College of Medicine, Department of Ophthalmology, Metabolic Recharge, 989 Story Road, Suite 8069, San Jose, CA 95122, United States of America

<sup>b</sup> Eselle Health, 7660 Fay Avenue H-829, La Jolla, CA 92037, United States of America

<sup>c</sup> Pennington Biomedical Research Center of the Louisiana State University, 6400 Perkins Road, Baton Rouge, LA 70808, United States of America

<sup>d</sup> Retinal Diagnostic Center, 200 Jose Figueres Avenue, San Jose, CA 95116, United States of America

<sup>e</sup> University of Texas Health Science Center at Houston, McGovern Medical School, Department of Internal Medicine, MSB 1.122, 6431 Fannin, Houston, TX 77030, United States of America

## ARTICLE INFO

### Keywords:

Diabetic retinopathy  
Physiologic insulin Resensitization

## ABSTRACT

We followed two patients with diabetic retinopathy over the course of their treatment with physiologic Insulin resensitization. Both patients showed improvement of their diabetic retinopathy, after treatment.

## 1. Introduction

Diabetic retinopathy (DR) is a common eye disease in the United States. The National Eye Institute predicts that over 11,000,000 Americans will have this disease by 2030.<sup>1</sup> A study conducted at the Centers for Disease Control found that DR affected one-third of diabetics over age 40 and 655,000 persons had sight threatening DR.<sup>2</sup> The condition occurs in persons who have had diabetes for many years.<sup>3</sup> The progression of DR is associated with other conditions indicating worsening of diabetes including hypertension, dyslipidemia and elevated HbA1c.<sup>4</sup> It has been shown that DR can be reversed with intensive glycemic control in a clinical trial setting<sup>5</sup> but the methods are not practical in the real world of clinical practice. There are also treatments that slow the progression of DR to proliferative diabetic retinopathy (PDR). The more advanced states of DR cannot be reversed.<sup>6</sup>

An Ophthalmologist noted during regular follow up visits that a patient with type 2 diabetes with moderate DR and another type 2 diabetic with proliferative diabetic retinopathy showed reversal of these conditions. These changes in both patients occurred after undergoing a diabetes therapy that has been termed Physiologic Insulin Resensitization (PIR). The treatment utilizes periodic cycling of up to 3 IU of regular fast acting insulin infused intermittently between 4 and 8 min for 2 to 4 Hours. Individuals with type 2 diabetes begin these infusion treatments

on a weekly basis and gradually transition to one treatment every 4–6 weeks, depending on patient response. Oral glucose is given to patients to simulate a meal and keep blood glucose levels in a prescribed range during the insulin infusion process. Patients are observed during the process until glucose levels are stable after the physiologic insulin infusion is administered. A more complete description of the basis of the treatment and its outcomes can be found in a paper by Greenway et al.<sup>7</sup> The treatment has been effective in reversing diabetes associated peripheral neuropathy,<sup>8</sup> healing of foot ulcers<sup>9</sup> and reversal or slowing progression of nephropathy.<sup>10–12</sup> Until the current paper, changes in DR has not been documented following the use of PIR.

## 2. Methods

Given a clinical impression of two cases of reversal of DR, the patient records of these patients were reviewed. Fundus photographs at entry to the treatment with PIR were compared to subsequent photos to document the changes in the retina. The changes in the retina were evaluated by two board certified ophthalmologists, one of whom was a retinal specialist. They used the International Clinical Disease Severity for Diabetic Retinopathy Scale<sup>13</sup> to evaluate the severity of the patients' retinopathy prior to and after treatment with PIR. One patient also had optical coherence tomography from before and after undergoing PIR

\* Corresponding author.

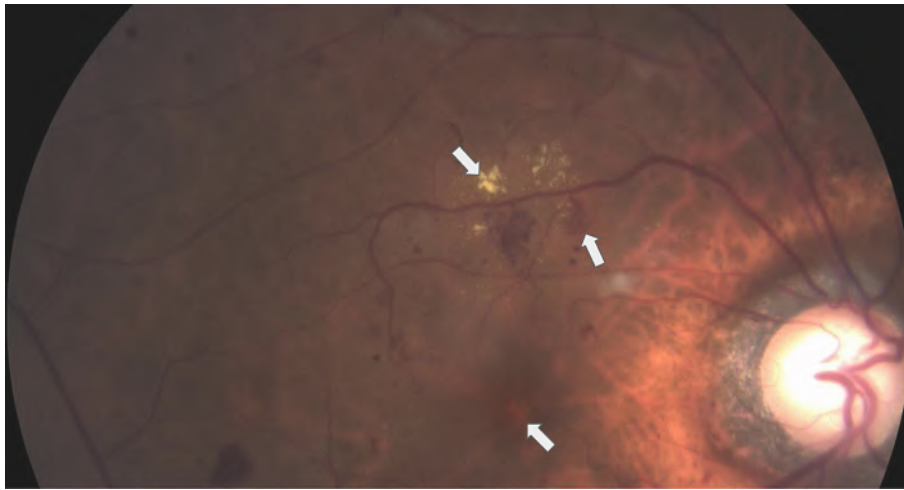
E-mail addresses: [randal.pham@cnsu.edu](mailto:randal.pham@cnsu.edu) (R.T. Pham), [slewis@esellehealth.com](mailto:slewis@esellehealth.com) (S.T. Lewis), [Frank.Greenway@pbrcc.edu](mailto:Frank.Greenway@pbrcc.edu) (F. Greenway), [amr@dessouki.com](mailto:amr@dessouki.com) (A. Dessouki), [richard.m.grimes@uth.tmc.edu](mailto:richard.m.grimes@uth.tmc.edu) (R.M. Grimes).

<https://doi.org/10.1016/j.jdiacomp.2023.108549>

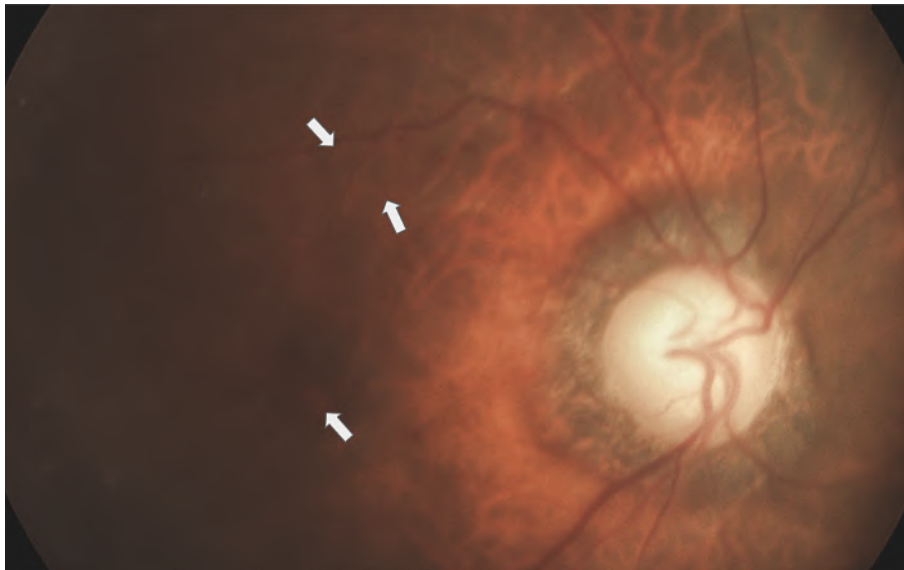
Received 15 February 2023; Received in revised form 13 June 2023; Accepted 14 June 2023

Available online 25 June 2023

1056-8727/© 2023



**Figure 1..** Photo of patient 1 prior to receiving PIR.



**Figure 2..** Photo of Patient 1 after receiving PIR.

and these were used to further validate changes. Both patients provided written consent to having their conditions described and their photos used in this report.

### 3. Results

Patient 1 was a 69-year-old Vietnamese-American male who had been diagnosed with diabetes for 20 years. The patient developed severe proliferative diabetic retinopathy in 2017. The patient could not be treated with anti-Vascular Endothelial Growth Factors (aVEGF) because of his allergic reaction to the medication. The patient declined pan-retinal photocoagulation because he wanted to preserve his peripheral vision. At the time he began PIR he had sufficient visual impairment to cause him to reduce his driving. This patient began PIR in December of 2017 and had the fundus photo shown in Fig. 1 at that time. The patient was rated as having severe macular edema using the International Clinical Disease Severity for Diabetic Retinopathy Scale On 1/8/21. This was also examined with optical coherence tomography which was consistent with the scale. (See Fig. 5) The patient had the fundus photo shown in Fig. 2 On 1/8/21. Using the same scale, the patient had reversed his DR to mild non-proliferative diabetic retinopathy. The

optical coherence tomography taken at that time was consistent the scale. (Fig. 6) The last PIR treatment that the patient received was on 12/30/20. When he began PIR his HbA1c was 9.2. On 3/14/21 his HbA1c was 6.3. The patient's visual acuity had not worsened since that time. He is now driving under all light and weather conditions with no limitations.

Patient 2 was a 79-year-old Vietnamese-American female who had been diagnosed with diabetes for 7 years. This patient began receiving the same PIR treatment as patient 1 in October of 2021. Her pretreatment fundus photo is shown in Fig. 3. The patient was evaluated as having moderate nonproliferative diabetic retinopathy on the International Clinical Disease Severity Scale for diabetic retinopathy. Because she was early in her DR, optical coherence tomography was not done. Her fundus photo taken on 6/9/22 showed the retinopathy was reversed to no apparent retinopathy. See Fig. 4. The patient received the latest treatment on 6/4/22. The patient reports that her visual acuity improved after treatment. Her HbA1c was 6.6 prior to being treated with PIR and 6.3 after treatment.

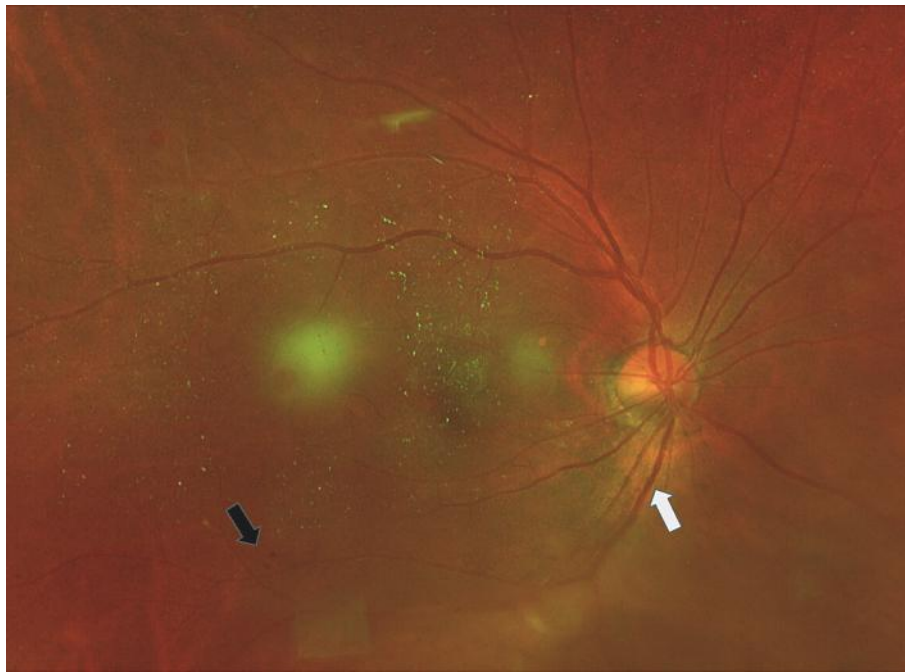


Figure 3.. Photo of patient 2 prior to receiving PIR.

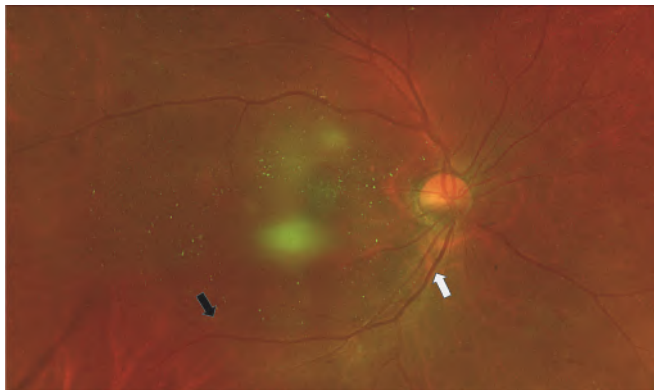


Figure 4.. Photo of patient after receiving PIR.

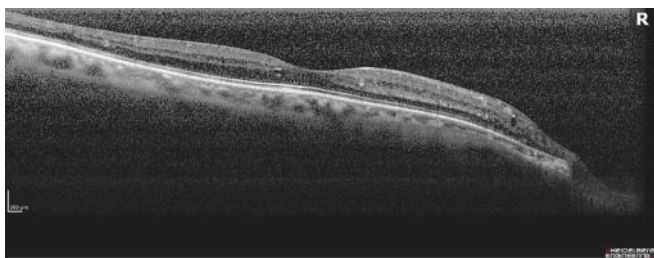


Figure 5.. Optical coherence tomography of patient 1 prior to receiving PIR.

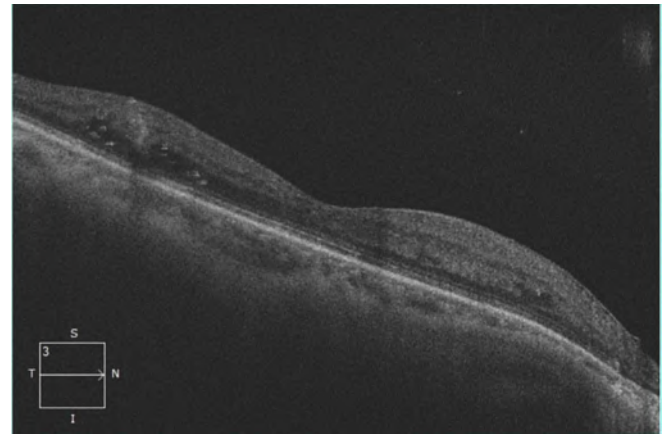


Figure 6.. Optical coherence tomography of patient 1 after receiving PIR.

remarkable to warrant further studies on the effectiveness of PIR on DR. Such studies would need to document retinal changes at scheduled times and investigate what other factors may have caused the changes (e.g., other treatments, behavioral changes, etc.) These studies should contain larger numbers of subjects from more diverse backgrounds. Additionally, there should be long term follow up to determine whether the changes are permanent or will revert to the previous, more severe state at a later time.

**Declaration of competing interest**

None of the authors have a conflict of interest.

**References**

1. National Eye Institute. Diabetic Retinopathy Tables. <https://www.nei.nih.gov/learn-about-eyehealth/outreach-campaigns-and-resources/eye-health-data-and-statistics/diabetic-retinopathy-dataand-statistics>. Accessed October 16, 2021.
2. Centers for Disease Control. Diabetic Retinopathy. <https://www.cdc.gov/visionhealth/pdf/factsheet.pdf>. Accessed October 16, 2021.

**4. Conclusion**

Physiological Insulin Resensitization appeared to have reversed diabetic retinopathy in these two patients. While these results have been found in only two patients, they follow a pattern of remarkable changes reported in other small-scale studies of diabetes related conditions such as peripheral neuropathy, chronic kidney disease, and rapid wound healing following administration of PIR. The results are sufficiently

- 3 Jones CD, Greenwood RH, Misra A, Bachmann MO. Incidence and progression of diabetic retinopathy during 17 years of a population-based screening program in England. *Diabetes Care*. 2012;35:592–596.
- 4 Lee R, Wong TY, Sabanayagam C. Epidemiology of diabetic retinopathy, diabetic macular edema and related vision loss. *Eye Vis (Lond)*. 2015 Sep;30:17.
- 5 Nathan DM, DCCT/EDIC Research Group. The diabetes control and complications trial/epidemiology of diabetes interventions and complications study at 30 years: overview. *Diabet Car*. 2014 Jan;37:9–16.
6. National Health Service. Diabetic retinopathy. <https://www.nhs.uk/conditions/diabeticretinopathy/stages/>. Accessed October 17, 2021.
- 7 Greenway F, Loveridge B, Grimes RM, Tucker TR, Alexander M, Hepford SA, et al. Physiologic insulin resensitization as a treatment modality for insulin resistance pathophysiology. *Int J Mol Sci*. 2022;23:1884.
- 8 Tucker T, Hadley J, Alexander M, Lakey JRT, Loveridge B. Case series: reversal of diabetic neuropathy utilizing physiologic insulin resensitization. *Int J Diabetes Metab Disord*. 2021;6:160–163.
- 9 Elliott J, Elliott A, Cimler A, Zaias N, Escovar S. Extraordinary rapid wound healing time in diabetic patients treated with microburst insulin infusion. *Int Res J Publ Health*. 2018;2:9.
- 10 Villaverde Z, Tucker T, Hepford SA, Lakey JRT, Hinman RH. Improved kidney function following physiologic insulin resensitization treatment modality. *J Endocrinol Disord*. 2021;5:4.
- 11 Manassis A, Hanna MR, Sachsenheimer D, Do L, Lewin JC, Steiner SS, et al. Pulsatile insulin infusion as a treatment option for patients with type 2 diabetes and stage III kidney failure - results from a pilot study. *Endocrinology and Metabolic Research*. 2021;6:5–49.
- 12 Quach S, Manassis A. Pulsatile insulin treatment as a treatment option for patients with type 2 diabetes and stage 3 kidney failure. *Diabetes*. Jun 2021;70. Supplement 1.
- 13 Wilkinson CP, Ferris 3rd FL, Klein RE, et al. Proposed international clinical diabetic retinopathy and diabetic macular edema disease severity scales. *Ophthalmology*. 2003 Sep;110:1677–1678.